

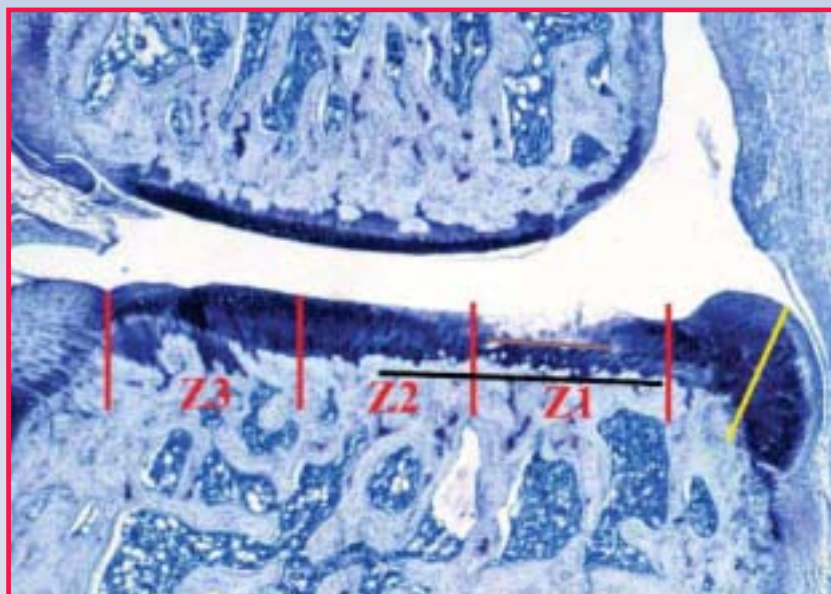Fig. 1. Photomicrograph of knee joint that has been assessed histologically for cartilage degeneration and osteophyte formation. The red lines divide the tibial plateau into 3 zones: Z1, Z2, and Z3. A micrometer measurement is taken across areas of degeneration; the purple line denotes the significant matrix loss. The osteophyte formation measurement is denoted by the yellow line.

## Decalcified Bone Sections in Surgically Induced Osteoarthritis in Rat

Amy Rutledge, BS, HTL(ASCP)  
Elizabeth Chlipala, BS, HTL(ASCP)  
Premier Histology Laboratory, LLC  
University of Colorado  
Boulder, CO  
[lizchlipala@premierhistology.com](mailto:lizchlipala@premierhistology.com)

### Introduction

Osteoarthritis (OA) is a degenerative joint disease that causes the breakdown of the joint's cartilage. It is one of the oldest and most common types of arthritis currently affecting more than 20 million adults in the United States, and estimated by 2030 to affect 70 million Americans.<sup>1</sup> The surgically induced animal model of osteoarthritis in rats is used to study the pathogenesis of cartilage degeneration and evaluate potential antiarthritic drugs for clinical use.<sup>2</sup> By creating a medial meniscus tear surgically, one can study the kind of rapid and severe cartilage degeneration that occurs in some stages of human osteoarthritis.<sup>1</sup> These morphological changes can only be demonstrated through the histological preparation of the knee joint. Histological evaluation of the decalcified, paraffin-embedded toluidine blue-stained sections is performed to determine the severity of cartilage degeneration, the presence of osteophyte formation, and the efficacy of a potential drug.

Managing Editor, Gilles Lefebvre  
Scientific Editor, Vinnie Della Speranza,  
MS, HTL (ASCP) HT, MT

### Materials and Methods

#### Animal Model

The surgically induced medial meniscal tear procedure is performed on 300-400 gram rats. The medial collateral ligament is transected and the medial meniscus is reflected medially toward the femur and then cut. The cut is made through the full thickness to simulate a complete tear. As a result, rapid cartilage degeneration occurs within 3 weeks postsurgery.<sup>1,3</sup> Testing of potential antiarthritic drugs is initiated prior to or after surgery and is continued for 3 weeks with 20 animals per treatment group to account for variability in lesion severity. At necropsy, the right knee joint is trimmed of muscle and connective tissue, and the patella is removed to allow proper fixation of the joint. The femur and tibia are transected with a rongeur some distance from the joint to avoid fragmentation of the bone around the joint area. The joint is then placed in 10% neutral buffered formalin (fixative) and allowed to assume a natural degree of flexion.<sup>1,2</sup>

### IN THIS ISSUE

Decalcified Bone Sections in Surgically Induced Osteoarthritis in Rat .....	1
Preparation and Snap Freezing of Murine Tissues for Research Immunohistochemistry and Routine Hematoxylin & Eosin Staining .....	4
A Novel Technique to Embed Tissues for Frozen Section Cryotomy .....	7
Debunking an Urban Legend in Bone and Cartilage Histotechnology: Safranin O Fast Green <i>Will</i> Stain Proteoglycans After EDTA Decalcification .....	10
Immunohistochemical Staining Techniques to Demonstrate <i>Treponema pallidum</i> Spirochetes .....	14

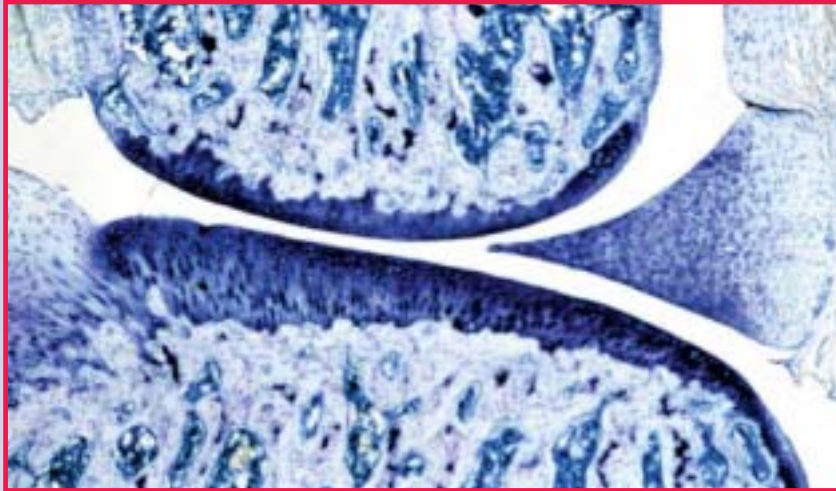


Fig. 2A. Photomicrograph of medial aspect of a normal rat knee joint. There is no chondrocyte or proteoglycan loss. Toluidine blue. Original magnification 50X

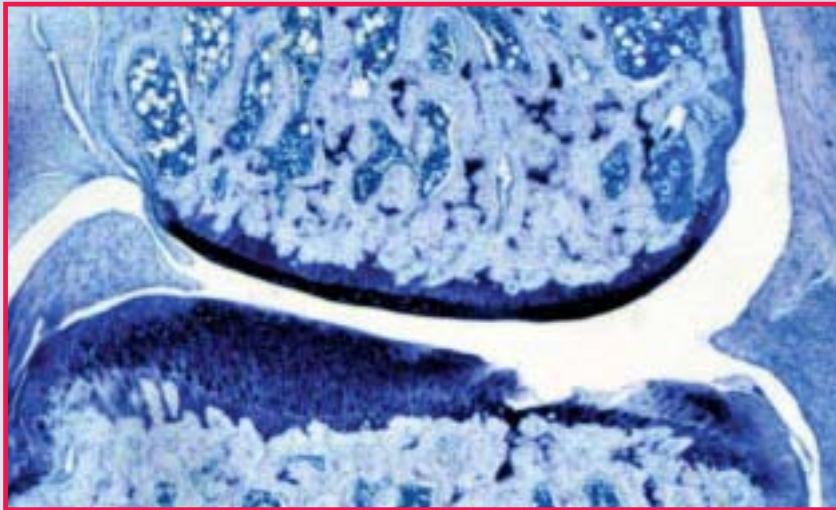


Fig. 2B. Photomicrograph of medial aspect of knee joint from rat which had unilateral medial meniscal tear surgery 3 weeks previously. Focal severe cartilage degeneration, characterized by chondrocyte and proteoglycan loss as well as fibrillation, is present on the medial tibial plateau. Toluidine blue. Original magnification 50X

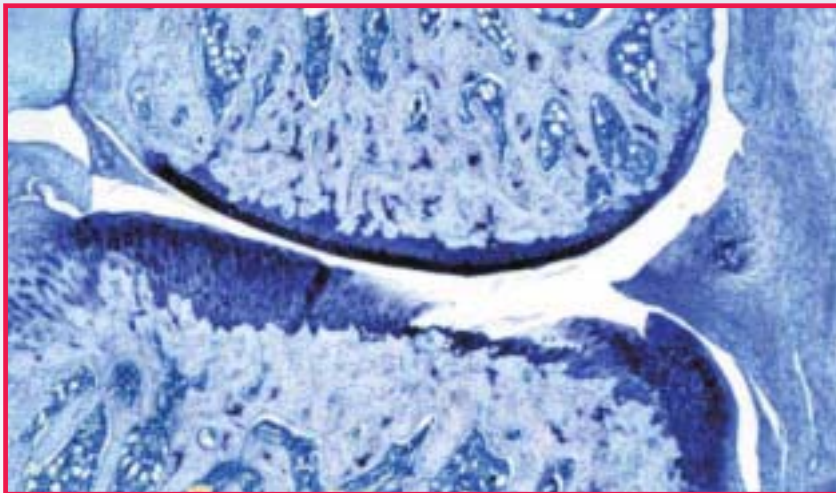


Fig. 3. Photomicrograph of the medial aspect of a knee joint from rat, which had medial meniscal tear surgery. Toluidine blue. Original magnification 50X

### Histology

The knee joints are fixed in 10% neutral buffered formalin for 48 hours and then placed into 5% formic acid for 3-6 days to decalcify. Once decalcified, the knee joints are cut into approximately 2 equal halves in the frontal plane, using the collateral ligament as a landmark.

The joints are processed for paraffin embedding and sectioned at 8  $\mu$ m for toluidine blue staining. An initial section is cut followed by two step cuts at 200  $\mu$ m intervals, yielding a total of 3 sections per knee.

### Results

The knee joints are evaluated for severity of the medial femoral and medial tibial cartilage degeneration, and also for osteophyte formation. The primary area that is evaluated for cartilage damage is the medial tibia. The medial tibia is divided into 3 zones (inner, middle, outer), and each zone is scored separately. The following system is used to score the cartilage degeneration in each zone.

Initially, the depth of chondrocyte and proteoglycan loss with fibrillation is calculated by using the following criteria:

- 1=minimal; superficial zone only
- 2=mild; extends into the upper middle zone
- 3=moderate; well into the middle zone
- 4=marked; into the deep zone but not to tidemark
- 5=severe; full thickness degeneration to tidemark

Next, the area of cartilage degeneration involved is assessed as 1/3, 2/3, or 3/3 of the surface of the section. The score is then multiplied by 1, 2, or 3 to reflect the extent of the tibial plateau that is involved.

For tibial degenerative change, a micrometer measurement is taken across the portion of medial tibia that demonstrates any cartilage degeneration. Then a second

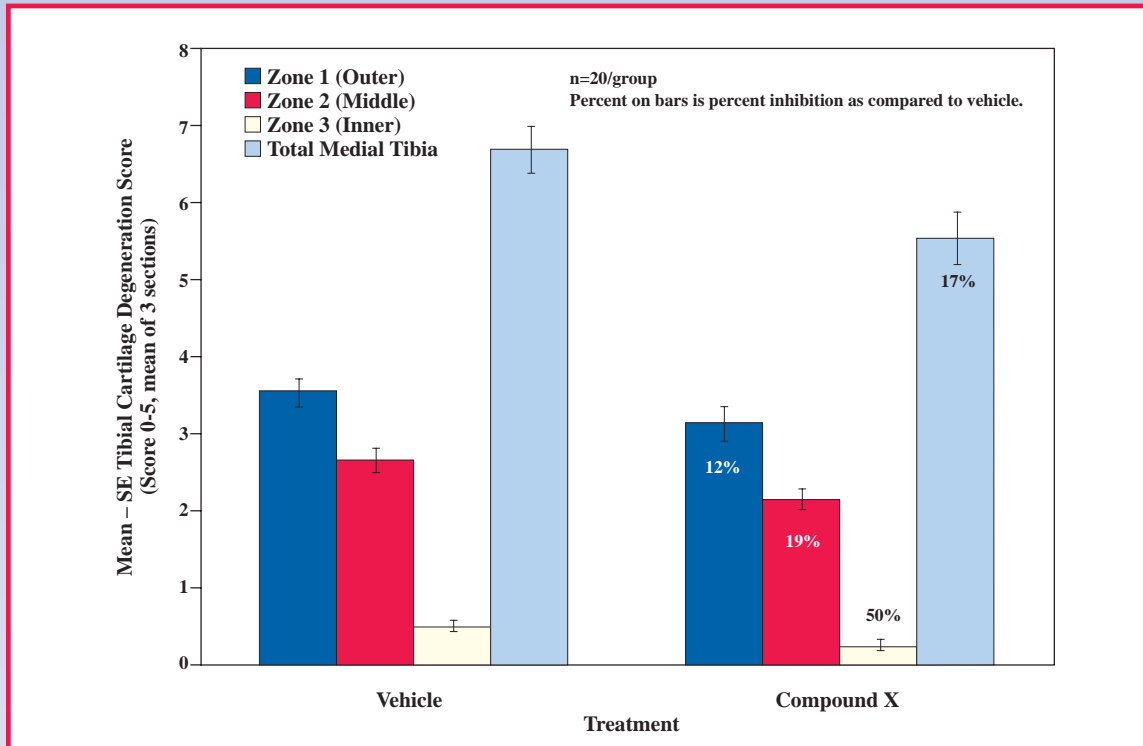


Fig. 4A. Cartilage degeneration score of sample vehicle and compound data. Graphical representation of the major histopathological parameters including the mean, standard error, statistical analysis, and percent inhibition.

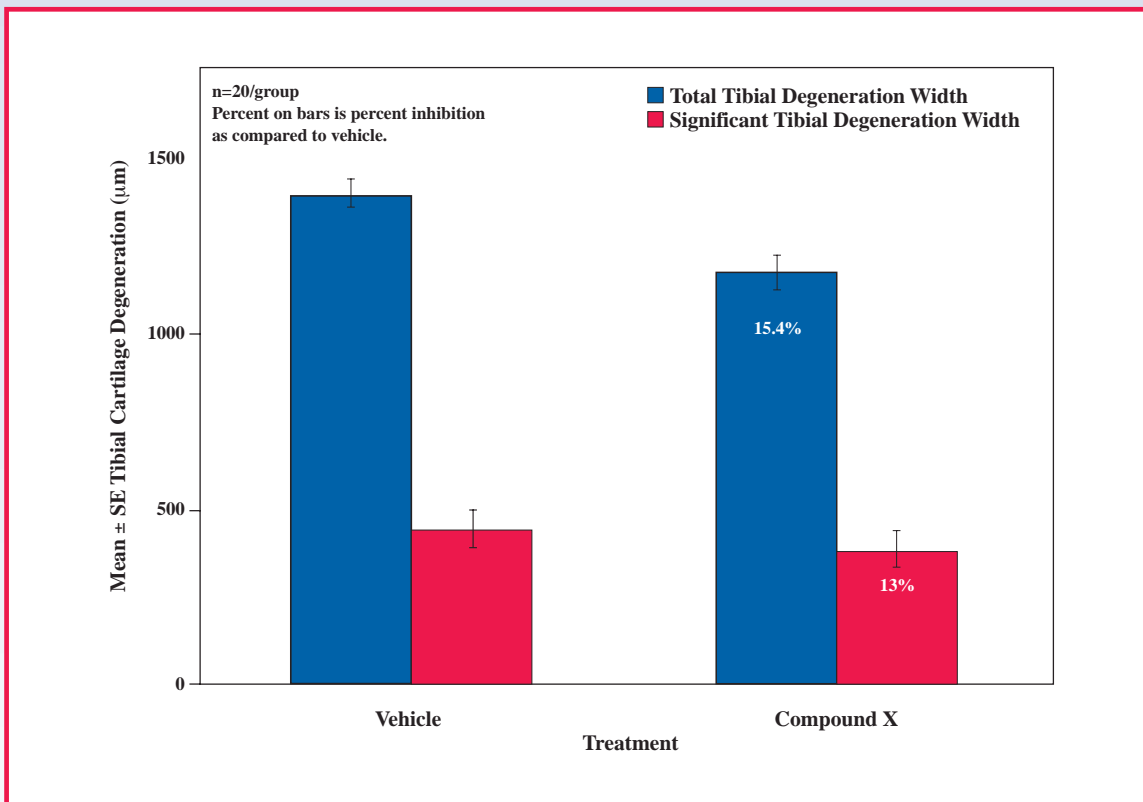


Fig. 4B. Cartilage degeneration width of sample vehicle and compound data.

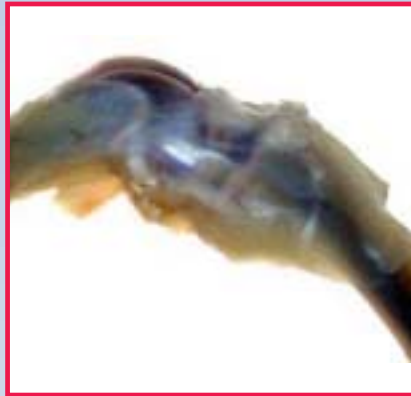

Fig. 5. Gross photograph of rat knee demonstrating normal flexion. The majority of the connective tissue and muscle have been removed along with the patella to allow penetration of the fixative into the joint.



Fig. 6A. After several days in decal, the ends of the bone are trimmed and the knee joint is placed in forceps along the patellar groove to hold the orientation while cutting in half. The collateral ligament is used as a landmark to achieve two equal halves, which is a critical step in the grossing.

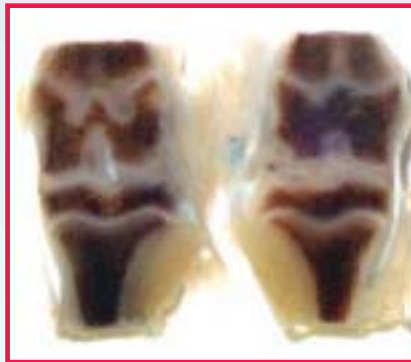


Fig. 6B. Demonstration of what is achieved when using the collateral ligament as a guide to cut the knee joint into two equal halves.

measurement is taken of the area of degeneration that has resulted in significant matrix loss (greater than 50% of the cartilage thickness) in an effort to further quantitate the more serious changes.

Osteophytes are measured and categorized into small, medium, and large using an ocular micrometer.

Osteophyte evaluation is determined by the following criteria:

- 1=small, up to 299  $\mu\text{m}$
- 2=moderate, 300-399  $\mu\text{m}$
- 3=large,  $\geq 400 \mu\text{m}$

### Conclusions

The information acquired from the histopathology allows the evaluation of potential antiarthritis drugs. The results acquired from this animal model of disease show the effects of compounds on proteoglycan degradation and osteophyte formation. In addition, activity of metalloproteinase inhibitors and other antiarthritis compounds may be detected. This rat model mimics human traumatic osteoarthritis and demonstrates morphological changes of pathogenesis that compare to human disease.

Since the data generated from the histology cannot be captured by any other means, it is important that each specimen is handled appropriately. Great care must be taken to assure that the knee joint is bisected into two equal halves, and processed and embedded properly so that the subsequent levels demonstrate lesion severity with consistency.

### References

1. Bendele AM, McComb J, Gould T, et al. Animal models of arthritis: relevance to human disease. *Toxicol Pathol.* 1999;27:134-142.
2. Clarke KA, Heitmeyer SA, Smith AG, Taiwo YO. Gait analysis in a rat model of osteoarthritis. *Physiol Behav.* 1997;62:951-954.
3. Janusz MJ, Bendele AM, Brown KK, Taiwo YO, Hsieh L, Heitmeyer SA. Induction of osteoarthritis in the rat by surgical tear of the meniscus: inhibition of joint damage by a matrix metalloproteinase inhibitor. *Osteoarthritis Cartilage.* 2002;10:785-791. Errata in: *Osteoarthritis Cartilage.* 2002;10:905. *Osteoarthritis Cartilage.* 2003;11:299.

## Preparation and Snap Freezing of Murine Tissues for Research Immunohistochemistry and Routine Hematoxylin & Eosin Staining

Gayle Callis, MT, HTL(ASCP)HT  
 Veterinary Molecular Biology  
 Montana State University  
 Bozeman, MT  
[gcallis@montana.edu](mailto:gcallis@montana.edu)

Murine tissues can present histotechnicians with multiple cryomicrotomy problems ranging from the initial tissue collection to the final frozen section. Formalin-fixed, paraffin-embedded (FFPE) tissues are unusable when immunohistochemical (IHC) staining for rat anti-mouse-CD<sub>4</sub> and -CD<sub>8</sub> lymphocytes is needed. Antigen unmasking and enzyme digestion are unsuccessful at recovering these antigens. These murine CD markers are notorious for always giving negative results after FFPE tissue preparation. Because our laboratory routinely stains for CD<sub>4</sub> and CD<sub>8</sub> along with a panel of other CD markers on serial sections from a single tissue sample, we have abandoned FFPE tissues in favor of cryomicrotomy methods. This article will discuss tissue collection, snap freezing, and frozen block storage methods used successfully in our laboratory.

### Tissue Collection

Animal euthanasia is performed according to strict protocols set forth and monitored by our university animal care committees. After euthanasia, tissues are dissected out quickly and snap frozen within minutes to prevent damaging autolysis and potential antigen diffusion. Most tissues are removed without problems but some organs must be handled in special ways. Prior to embedding, the plastic Tissue-Tek® Cryomold® (Sakura Finetek, Torrance, CA),

designed to support tissue cassettes, is trimmed to remove the 3 plastic edges; it now resembles the round Tissue-Tek® Cryo<sub>3</sub>® biopsy mold with extended tab. This tab is held with forceps during snap freezing and the trimmed mold is easier to insert into a 50 ml tube for freezer storage. Smaller tissues such as lymph node, spleen, liver slices, and brain (either whole or bisected at midline) are embedded separately. Different tissues, such as spleen and intestine, have different sectioning qualities and are *never* put together in the same block. The following tissues require special handling in order to cryosection properly.

**Whole lung** is filled with OCT® (Sakura Finetek, Torrance, CA) by exposing the trachea and making a tiny V-shaped cut on top of the trachea with care—**do not** cut across this tubular structure. The severed trachea retracts into the chest area and cannot be retrieved easily for filling the lung with OCT. A dulled 18 gauge hypodermic needle attached to a 3 ml syringe is inserted into this V cut and pushed gently toward the lung without puncturing the trachea wall.

Approximately 2.5 ml OCT is injected slowly into the lung and observed carefully to avoid overfilling lung air spaces. The pinkish-white *deflated* lung expands into a translucent, *inflated* lung. Delicate alveoli are severely damaged by overfilling the lung with OCT. To prevent OCT leakage, a mosquito hemostat forceps is used to clamp off the trachea as the needle is pulled out. The lung is removed from the pleural cavity and separated from the heart. The lung and heart are embedded in OCT separately in appropriately sized Cryomolds.

**Brain** can be embedded whole, bisected midsagittally, or cut into transverse/cross-sections from front to back of the brain.

**Spinal cord** is removed by severing the vertebral column at the base of

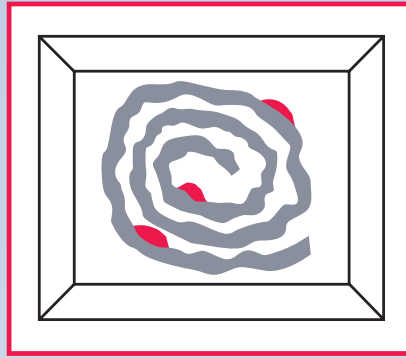


Fig. 1. Concentric circle orientation of small intestine with Peyer's patches (red) located on the outer serosal surface.

the skull near the last lumbar vertebra. The cord is forced out of the vertebral column by injecting phosphate buffered saline (PBS) into the lumbar vertebral opening so the cord ejects out of the wider cervical vertebral opening. The cord is cut into shorter 3 mm lengths and embedded in a small amount of OCT to maintain a flat, side-by-side orientation of these pieces. Prior to sectioning, cord blocks are turned on end and surrounded by extra OCT on the block holder to obtain transverse (cross) sections of the spinal cord.

**Small intestine** (whole) is transected below the stomach and above the cecum and dissected out carefully to avoid puncturing the intestine. The entire intestine is rinsed with PBS to remove fecal matter, followed by injection of OCT into the lumen using a dull 16 gauge needle on a 10 ml syringe. Avoid air bubbles in the syringe and inside the gut lumen. We prefer the intestine distended with OCT for midsagittal sectioning, which reveals Peyer's patches (gut-associated lymphoid tissue, or GALT) at both the outer (serosal) and inner (luminal) surfaces with distinct intestinal villi. The duodenum is distinguished by a tiny constriction of small intestine just before the jejunum. Approximately 5 to 6 lengths of intestine are cut and each length is oriented into a concentric circle in an empty, large Cryomold (Fig. 1). Each length is labeled as to

approximate location along the small intestine, eg, duodenum (D), jejunum (J1, J2), and ileum (I1, I2). It is important to note that needle gauge (size) will vary according to the age of the animal, with younger animals needing a smaller gauge (and conversely, a larger gauge needed for older animals), in order to have a tight fit into either the intestine or trachea lumen. Using the correct needle gauge permits easy insertion and prevents tearing of tissue and leaking of OCT or PBS during injection procedures.

**Calcified bone** can either be embedded directly into OCT or coated with 4% polyvinyl alcohol (PVA, water soluble, 35,000 to 70,000 MW, Sigma), then snap frozen without further embedment in OCT. We successfully substituted 4% PVA with OCT diluted 1:1 with PBS. A dry ice/hexane immersion freezing method is used for bone.<sup>1,2</sup> Bone can shatter if frozen directly in liquid nitrogen (LiqN<sub>2</sub>) or 2-methyl butane cooled by LiqN<sub>2</sub>. Mouse nasal turbinates are too large for Cryomolds so they are embedded with the nose end oriented on the bottom of the deeper 22 x 40 mm Peel-A-Way® disposable molds (Polysciences, Warrington, PA). This results in a longer, potentially unstable block extending away from a metal chuck during cryosectioning. Bone blocks are mounted onto block holders with 2% methyl cellulose (Aldrich) for a firmer hold that helps prevent vibration during sectioning.

There is a caveat, however; not all cryomedia work well with our murine tissue applications. We discovered by trial and error that one cryomedium failed to hold distended intestine properly during cryosectioning and resulted in compressed gut frozen sections with distorted, torn villi. Another cryomedium always pulled away from spleen and other tissues during sectioning, yielding curled, folded tissue sections. For some reason, these cryomedia failed to interface with our mouse tissues



Fig. 2. A solid block of dry ice may be used to freeze tiny samples in molds containing OCT in order to obtain a totally flat block face.



Fig. 4. Plastic Petri dish (blue) is supported by a platform to prevent tipping into the LiqN<sub>2</sub> inside a styrofoam box.

during snap freezing, sectioning, or both. It is recommended that laboratories test several cryomedia to optimize their particular cryosectioning needs. Failure of a cryomedium for murine cryotomy does not mean that the medium is defective; it is more likely that the cryomedium was never tested initially for murine research applications, but only for human tissue application.

### Snap Freezing Methods

Our laboratory uses three snap freezing methods to produce as many as 30 or more blocks during a day's freezing session. We no longer use LiqN<sub>2</sub>-cooled 2-methyl butane because it is too time-consuming to recool the solvent between each block. Ultracold (-80°C) freezers and cryostats with Peltier or heat extractor devices are never used to snap freeze tissues for research purposes. The tissue freezes too slowly with these devices and tissue morphology is damaged due to water ice crystal formation, or freezing artifact. Although we have not repaired freezing artifact on murine tissues, one may want to try the recently published method for frozen tissue

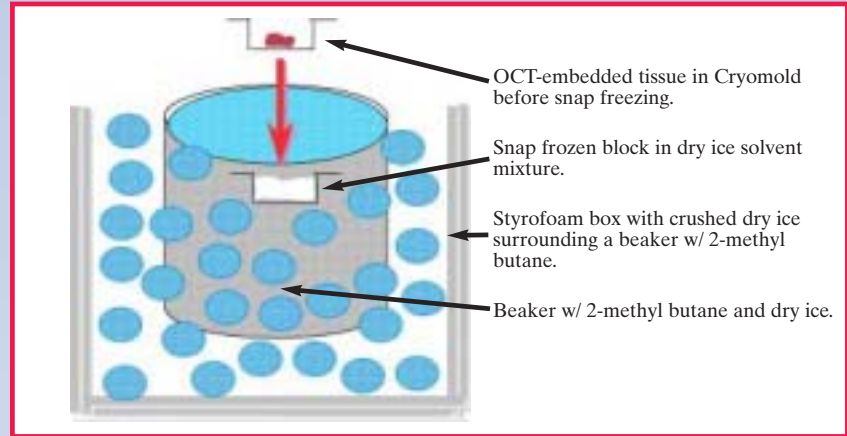


Fig. 3. Tissues may be frozen by immersing them into a beaker containing a mixture of dry ice/2-methyl butane. The beaker is surrounded by crushed dry ice in a styrofoam container.

recovery.<sup>3</sup> Sucrose (20%-30%) cryoprotection is not used to reduce water ice crystal formation with our fresh, unfixed tissues, but it is used with paraformaldehyde-fixed tissues destined for snap freezing.

We prefer snap freezing tissues by immersion in a dry ice/2-methyl butane mixture at approximately -78°C (Fig. 3). Hexane can be substituted for 2-methyl butane for any tissue and is commonly used to snap freeze calcified bone.<sup>1</sup> Immersion methods permit long freezing sessions, producing as many blocks as necessary without recooling the solvent. Another method that eliminates volatile, toxic solvents is a Petri dish floating in LiqN<sub>2</sub> (Fig. 4) with the dish supported to avoid tipping over into the LiqN<sub>2</sub>. We use either a large, solid aluminum block or a metal tube rack placed inside a styrofoam box with enough LiqN<sub>2</sub> added to the box so that the dish "canoes" on the surface of this ultracold liquid. The Petri dish separates the Cryomolds from direct contact with the LiqN<sub>2</sub>, which *must be kept out of the dish* to prevent cracked OCT and shattered tissues. Rarely, a solid dry ice block is used to snap freeze very tiny lymph nodes in small molds in order to have a totally flat block face (Fig. 2), even though the Petri dish/LiqN<sub>2</sub> method results in perfectly flat blocks. The dry ice block method<sup>4</sup> freezes tissue slower than either the immersion or

LiqN<sub>2</sub>/Petri dish method and will produce freezing artifact in larger tissues such as spleen. 2-Methyl butane and hexanes are major health, fire, and explosion hazards and must be stored in explosion-proof freezers.<sup>5</sup> Liquid nitrogen should be used in a well-ventilated room to avoid suffocating nitrogen fumes and also to prevent severe frostbite.

### Dry Ice Block Method<sup>4</sup>

A Cryomold with OCT-embedded tissue is used on a solid dry ice block (-78°C). Dry ice should be reflattened on a warm surface to avoid reusing the depression left by a previously frozen block. This will prevent a slowdown in freezing due to air space between the mold and the dry ice depression (see Fig. 2).

### Dry Ice/2-Methyl Butane

#### (or Hexane) Mixture

#### Immersion Method

A styrofoam box containing crushed dry ice surrounding a 2-methyl butane-filled beaker precools the solvent 30 minutes before adding dry ice *directly* into the solvent. **Do not add dry ice directly into room temperature 2-methyl butane or violent bubbling with spillage over beaker rim will create toxic solvent fumes.** Add enough dry ice to fill near the top edge of the beaker for easy recovery of frozen blocks. To snap freeze, the Cryomold with

OCT-embedded tissue is **lowered bottom first into the mixture until the OCT begins to freeze**, then it's allowed to sink onto the dry ice layer inside the beaker. After the block is frozen, remove and let it sit on dry ice or inside the cryostat chamber to evaporate the explosive solvent fumes before freezer storage (see Fig. 3).

#### *Petri Dish Floating in Liquid Nitrogen Method*

A metal platform surrounded by liquid nitrogen in a styrofoam box may be used to freeze OCT-embedded samples in a Petri dish. The platform transfers the cold to the sample while preventing the Petri dish from tipping into the liquid nitrogen. This method allows for better control of the freezing process since the sample can be seen throughout the freezing process, thus preventing the risk of overfreezing and cracking the block, which can happen with immersion methods if immersion is prolonged (see Fig. 4).

#### **Frozen Block Storage**

Our laboratory stores frozen blocks in an ultracold (-80°C to -86°C) freezer to prevent both antigenicity loss and freeze-drying of tissues. Sectioned blocks are resealed with a thin OCT layer, wrapped in aluminum foil, and returned to ultracold storage. Uncut blocks in trimmed Cryomolds are inserted into labeled 50 ml screw top centrifuge tubes and placed in styrofoam tube racks in the freezer (-80°C). We are fortunate that uncut and/or resealed blocks sectioned after 6 years of storage at -80°C still give excellent immunostaining results. Length of time for frozen block storage and successful immunostaining can be dependent on a given antigen's stability to withstand freezer storage conditions from one laboratory to another. Ultracold freezers are expensive and indefinite block storage presents a problem due to limited space. Low temperature freezers (-27°C to -40°C) are suitable for short-term (weeks or months)

storage. Automatic self-defrosting freezers or cryostat chambers are never used since freeze/thaw cycles can damage antigens and create freezing artifact. Unembedded frozen tissues can be wrapped tightly in aluminum foil and stored at -80°C until cryosectioning.

Overall, the dissection and snap freezing methods work well in our research laboratory. It is important to freeze murine and other animal species tissue rapidly for immunohistochemistry staining to avoid morphology-damaging freezing artifact and to stabilize antigens. Our snap freezing methods allow us to produce a large number of tissue blocks per day. Not all laboratories have ultracold freezers but they can purchase inexpensive, under-the-counter minifreezers without automatic defrost cycles to avoid using the auto-defrost freezers found inside many refrigerators.

This article provides some guidelines for initial preparation of tissues for cryomicrotomy. Histotechnology textbooks have other methods and discussion on cryomicrotomy.<sup>6</sup> Information on mouse dissection with excellent photographs is available at [www.eulep.org/Necropsy\\_of\\_the\\_Mouse/index.php](http://www.eulep.org/Necropsy_of_the_Mouse/index.php) or <http://icg.cpmc.columbia.edu/cattorette/Protocol/MousePathology/mainPageMousePath2.html>. A helpful and colorful mouse anatomy wall chart is available from the American Association for Laboratory Animal Science.

#### **References**

1. Dodds RA, Emery RJ, Klenerman L, Chayen L, Bitensky L. Selective depression of metabolic activities in cortical osteoblasts at the site of femoral neck fracture. *Bone*. 1990;11(3):157-161.
2. Tarpley J. Preparation and sectioning of undecalcified frozen rodent long bones and joints using a tape transfer system. *J Histotechnol*. 2003;26(1):41-56.
3. Fail R, Della Speranza V. A method to repair freeze artifact in skeletal muscle biopsies. *Histologic*. 2003;36(1):10-11.
4. Callis GM, Jutila M, Kurk S. Snap freezing tissue using dry ice and cryomolds. *Histologic*. 1991;21(3):253.
5. Skinner RA, Gaddy D. More than just a mandatory exercise. *Histologic*. 2003;36(1):1-4.
6. Gamble M, Bancroft J. *Theory and Practice of Histological Techniques*. 5th ed. WB Saunders; 2001.

## **A Novel Technique to Embed Tissues for Frozen Section Cryotomy**

**Carlette Mitchell Geddis,  
BS, HTL(ASCP)  
Medical University  
of South Carolina  
Charleston, SC  
[geddiscy@muscc.edu](mailto:geddiscy@muscc.edu)**

#### **Abstract**

Specimen orientation during embedding is key to achieving frozen sections of diagnostic quality. A specimen that has been oriented incorrectly may be irreversibly compromised if the error has not been discovered prior to sectioning. The first section cut may have ruined the entire specimen, such as the cutting away of mucosal surface. A method used in our laboratory can facilitate proper specimen orientation when embedding Mohs micrographic surgery samples for frozen section, and may also be applied to virtually any tissues requiring frozen section cryotomy.

#### **Introduction**

Mohs micrographic surgery is a specialized, highly effective technique for removing skin cancers. It was developed in the 1930s by Dr. Fredrick Mohs. Mohs surgery differs from other skin cancer treatments in that it permits the immediate and complete microscopic examination of the removed cancer tissue, ensuring that all roots and extensions of the cancer are eliminated.<sup>1</sup> Mohs surgery is commonly used in the treatment of skin cancers that recur after previous treatments have been used, and to preserve normal skin in cosmetic areas.

Laboratories employ a number of different strategies when embedding tissues for frozen section. In Mohs micrographic surgery, embedding is critical because the surgical margins must be checked and cleared before a




Fig. 1. A specimen arriving in the laboratory is compared to the surgeon's map to confirm correct orientation.



Fig. 2. The tissue is hydrated to prevent drying and to remove excess marking dye in order to make the epidermis more visible.

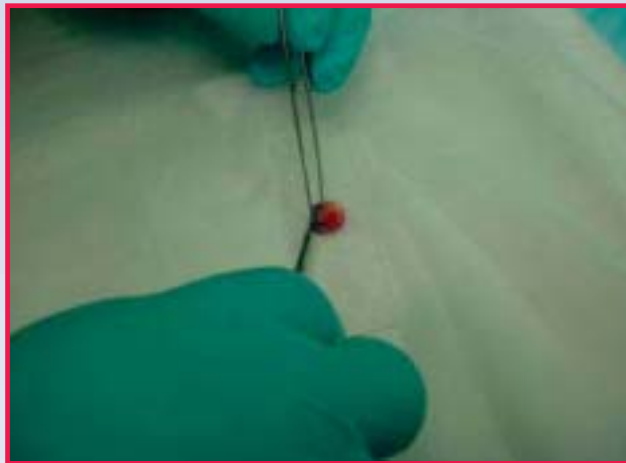


Fig. 3. The specimen is placed onto a glass slide, deep margin down. Relaxing cuts may be made to ensure that all margins will be in the same plane for sectioning.

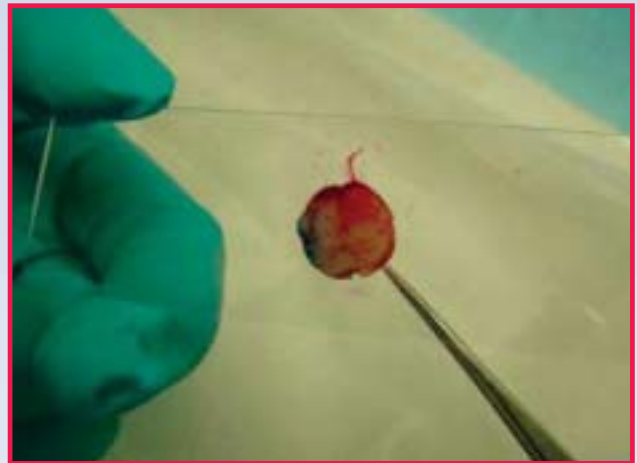

Fig. 4. Tissue must be checked to ensure that no air pockets exist under the tissue before freezing can be done.



Fig. 5A. Tissue is placed onto the cryostat freeze bar and lightly coated with OCT while a chuck is prepared. In this photo, the knife holder was used to facilitate photography only, and is not intended to be used in this technique.



Fig. 5B. A chuck is inverted onto the tissue sample as it begins to freeze.



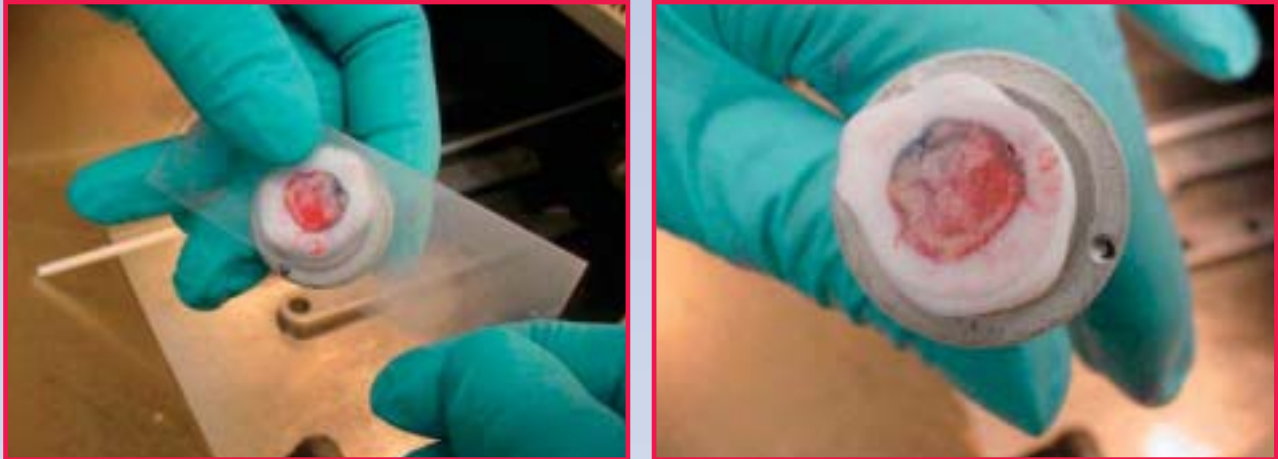


Fig. 6A and Fig. 6B. The thumb is used to warm the slide to separate the glass from the frozen block.

surgeon can declare a patient to be tumor free. This is best achieved by having the epidermal and deep margins oriented in the same plane within the frozen block. Our surgeons employ different colored tattoo inks to label the margins, which aids the lab staff in orienting the specimen.

#### Method

Samples for frozen section are oriented onto a glass microscope slide *prior* to embedding in OCT<sup>®</sup> (Sakura Finetek, USA, Torrance, CA), in the same way that a mold is used to embed tissues in paraffin when permanent sections are being performed. This method is illustrated in a series of photos to aid the reader in understanding how specimen orientation is maintained and frozen section embedding is achieved.

The specimen to be examined is divided, if needed, and marked with tattoo ink. Lines are drawn on the skin to show the source of these specimens and a map of the surgical site is drawn. The tissue and map are brought to the laboratory, and the technologist is now ready to embed.

**Step 1.** The histotechnologist carefully examines the resected biopsy that was obtained from the Mohs surgical procedure. The sample is then compared to the map provided by the surgeon to

ensure accurate orientation. The orientation, location, and patient information are reconfirmed before proceeding. To minimize the number of glass slides to be prepared, the block of tissue is kept as large as possible; however, if the technologist feels that the tissue specimen is too large to embed precisely, it can be subdivided to obtain smaller specimens (see Fig. 1).

**Step 2.** The tissue is hydrated with water or saline to prevent drying and to remove excess marking dye so that the epidermis is visible. It is important to dry off the excess water before the tissue is embedded to prevent freeze artifact from interfering with histologic interpretation. Once the excess dye has been removed, the embedding process begins (see Fig. 2).

**Step 3.** The specimen is placed onto a glass slide, deep margin down, and a chuck is labeled with the patient's name and corresponding accession number. The layer (sample) is carefully examined to ensure that the entire epidermal and deep margins are completely adhered to the glass slide. It is of utmost importance that the epidermis is teased down on the slide and the deep tissue is flattened and positioned into the same plane to yield a true and complete surgical margin upon microscopic examination. If the tissue is too thick, scoring and

relaxing cuts may be made in the specimen with a scalpel blade to ensure that the epidermis is teased down on the glass slide, along with the deep tissue (see Fig. 3).

**Step 4.** It is also important to check for air pockets that may form between the tissue and the glass slide. If air pockets are present, press firmly on the superior aspect of the tissue to expel the entrapped air, thus making contact between the tissue and the underlying glass slide (see Fig. 4).

**Step 5.** Next, the glass slide containing the inked specimen is placed onto the cryostat freeze bar and coated with a thin layer of OCT, which must be placed over all exposed surfaces and outer edges of the specimen. Avoid using excess OCT, which results in an enlarged frozen block face. A block that is too large will make sectioning more difficult and can result in section chatter. The OCT-covered specimen will turn from a clear to an opaque color. While this transformation is taking place, put the labeled chuck on the freeze bar and apply OCT. When the chuck and OCT-covered glass slide first appear opaque, flip the chuck onto the specimen-covered glass slide. Allow the specimen to freeze together with the cryostat at a temperature ranging from -28°C to -30°C (see Fig. 5A, 5B).

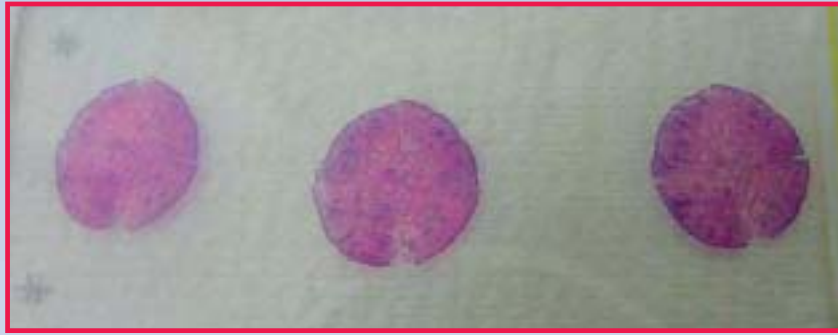

Fig. 7. The result is perfect sections representative of the entire sample containing all margins.

**Step 6.** Warmth from the histotechnologist's gloved thumb on the glass will allow the slide to be removed, leaving a smooth and level block face (see Fig. 6A, 6B). One should be able to see the entire tissue sample, which includes the epidermal edge, deep tissue, and inked margin. The chuck is now submerged into liquid nitrogen for approximately 3 seconds. There's no need for any additional OCT on the block face. The block is now ready for sectioning.

#### Discussion

There are several advantages to the glass slide embedding technique compared to the cryomold technique or the direct method (direct freezing onto the chuck on the freeze bar while flattening with a heat extractor), techniques that are often employed in many laboratories. The glass slide technique provides a block face that is immediately ready for sectioning without the need for trimming. Furthermore, the requirement that the epidermal and deep margins remain in the same plane makes it essential that the specimen orientation does not change during freezing—this cannot be ensured when the direct method is employed. When using glass slides, all manipulations are performed before any OCT is applied.

Because the tissue block face isn't covered with OCT in the glass slide embedding technique, the technologist is able to see the epidermal and deep margins before

sectioning begins. This decreases the likelihood of tissue being cut away, affording a chance to melt it down and re-embed if necessary, before sectioning begins. With other methods, including the direct freeze bar technique, the block face is obscured with excess OCT and the specimen is not visible until the block has been trimmed, which risks critical areas of the tissue being cut away.

The glass slide embedding technique is rapid and takes less time for the technologist to embed the specimen than in other freezing methods. Most important of all, it allows the surgeon to perform Mohs surgery on more complex, delicate, thin tissues, such as eye lids, due to the accuracy of the embedding and the conservative way the block is trimmed. Epidermis is seen immediately upon embedding, instead of a block face obscured by OCT.

Finally, the glass slide embedding technique is not only applicable to samples derived from Mohs micrographic surgery but may also be utilized for any tissues requiring frozen sectioning, including tiny needle biopsies. This helps avoid unnecessary tissue loss that can otherwise occur during the block trimming required with other freezing methods.

#### Reference

1. Gross KG, Steinman HK, Rapini RP, eds. *Mohs Surgery: Fundamentals and Techniques*. St. Louis, Mo: CV Mosby; 1998:324.

## Debunking an Urban Legend in Bone and Cartilage Histotechnique: Safranin O Fast Green Will Stain Proteoglycans After EDTA Decalcification

**Robert A. Skinner**  
 Dept. of Orthopaedic Research  
 University of Arkansas  
 for Medical Sciences  
 Little Rock, AR  
[Skinnerroberta@uams.edu](mailto:Skinnerroberta@uams.edu)

In today's electronic world information travels fast. All kinds of information. Good, bad, true, false—it all goes. Urban legends get passed from coast to coast with the click of a mouse. Perhaps you are familiar with some of these urban legends:

- Companies putting additives into soft drinks to create a legion of addicted people who will continue buying their product
- Waking up after a night of partying in a bathtub of ice with no kidneys because they were stolen and are now on their way to the highest bidder
- You can't do a Safranin O Fast Green (SOFG) stain on EDTA decalcified bone sections

Some of you probably read that last one and thought, "That isn't urban legend. EDTA destroys proteoglycans and SOFG is a proteoglycan stain, so of course you can't do this stain on EDTA decalcified material. After all, this information was posted on Histonet." However, this commonly held belief is simply incorrect.

I have done hundreds of SOFG stain runs since the 1980s. In all

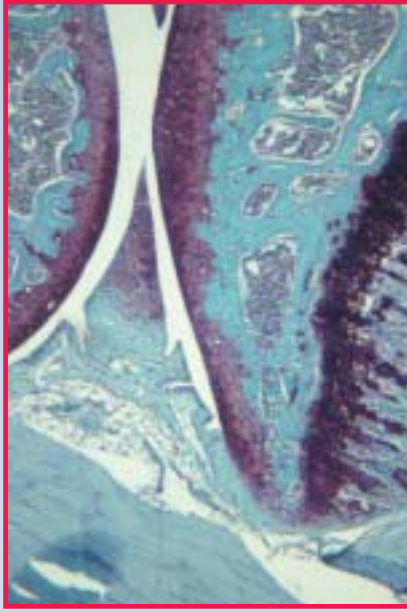

Fig. 1. SOFG on 5-micron section of 5% formic acid decalcified mouse knee. Proteoglycan-containing material stains red. Growth plate stains a darker shade than articular cartilage. Chondrocytes are identifiable. 20X

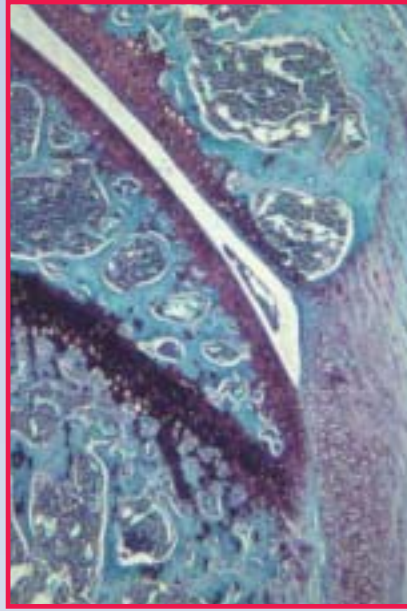

Fig. 2. SOFG on 5-micron section of 10% EDTA decalcified mouse knee. Proteoglycan-containing material stains red. Growth plate stains a darker shade than articular cartilage as in the formic acid decalcified prep, although arguably a different shade. Chondrocytes are equally as identifiable in either prep. 20X

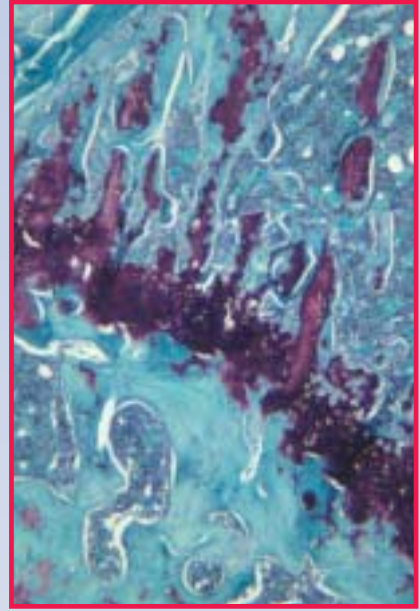


Fig. 3. SOFG on 5-micron section of 10% EDTA decalcified rat knee growth plate cartilage. Distinctive proteoglycan staining is present as denoted by the red areas. 20X

that time I cannot recall ever having had a procedure fail due to any specific decalcifying agent. I have worked with bone and cartilage throughout my career and am a frequent lecturer on this topic at the NSH symposium. In recent years I have received an increasing number of questions specifically pertaining to Safranin O Fast Green staining and EDTA.

I work in an orthopaedic research setting and am quite familiar with the popularity of EDTA as a decalcifying agent. In particular, one will achieve superior results when performing the Tartrate Resistant Acid Phosphatase (TRAP) reaction if this procedure is performed on EDTA decalcified sections rather than formic acid decalcified material. Many orthopaedic researchers also prefer sections from EDTA decalcified material for histomorphometric and image analysis. Since many orthopaedic histologic studies include both requirements, there is a tendency to hedge one's bet and

take the additional time and effort to decalcify via EDTA. Many in the clinical arena do not have the need for such specificity, but rather have a "need for speed," which is provided by decalcifiers whose primary constituent components are either formic acid or hydrochloric acid. Buffered or nonbuffered EDTA is typically regarded as being too slow to meet the turnaround time demands of the clinical laboratory.

All is well and good until some researcher wants the SOFG on EDTA decalcified material. That's usually when I get "the call" or "the e-mail."

This time the call came about two weeks after my bone processing workshop at the NSH symposium. An investigator at another facility had requested SOFG stains subsequent to the EDTA decalcification of harvested mouse knees. The technologist there remembered hearing something about EDTA and SOFG and

decided to call me to see if there was some way she could salvage her project.

My initial "knee-jerk" reaction was that there was no cause for concern. A recent report by Kalscheur<sup>1</sup> emphasized the value of SOFG stains in cartilage studies. However, I decided to examine the issue more closely by staining leftover tissues I had that had been decalcified in parallel in both EDTA and formic acid to see what, if any, staining differences might be observed. In theory, if EDTA destroys proteoglycans, then one might expect the EDTA decalcified slides to be faintly stained, if at all.

To avoid bias, all of the mouse slides in my study were stained in the same stain run with our standard control. I included tissue from different species to evaluate species variability. The slides were examined by Dr. Larry Suva, our lab director, in a blind review to avoid observer bias.

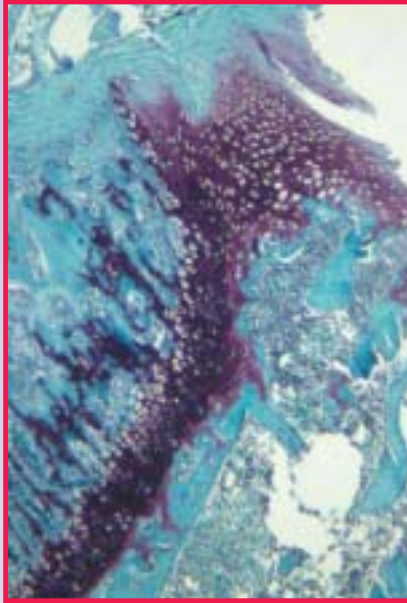

Fig. 4. SOFG on 5-micron section of 14% EDTA decalcified rat knee growth plate cartilage. Distinctive proteoglycan staining is present as denoted by the red areas. Note the tinctoral differences within the same species between the two EDTA protocols. 20X

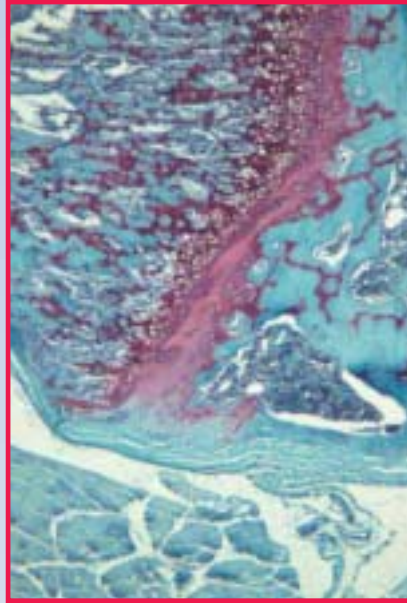


Fig. 5. SOFG on 5-micron section of 5% formic acid decalcified rat knee growth plate cartilage. Distinctive proteoglycan staining is present as denoted by the red areas. Note the tinctoral differences between rat and mouse in similar zones in all figures. 20X

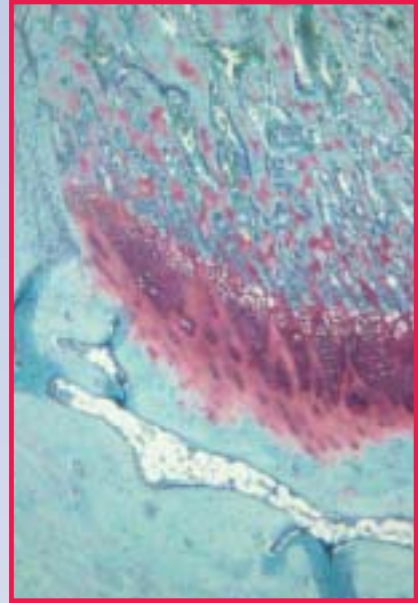


Fig. 6. SOFG on 5-micron section of 5% formic acid decalcified rabbit growth plate cartilage. Note the tinctoral differences as compared to the previous figures. 20X

The evaluated samples included several mouse knees and rat knees exposed to various decalcification protocols (EDTA decalcified for approximately 3 weeks, endpoint determined by x-ray, another decalcified for 6 weeks using a 14% EDTA solution pH 7.4 and decalcified in 5% formic acid), as well as rabbit wrist and human femoral head, both decalcified in 5% formic acid.

In this examination Dr. Suva was able to identify and count chondrocytes with ease from among the various preps; however, he noted that the colors in the formic acid decalcified samples were much nicer (Fig. 6). We concluded that there was a noticeable tinctoral difference between species, but little difference between EDTA and formic acid decalcification within the same species for the purpose of chondrocyte identification. A review of the Kalscheur images likewise revealed similar staining variability.

Dr. Ralph Sanderson, an expert in Syndecan and proteoglycan

research at the University of Arkansas for Medical Sciences, is unequivocal that EDTA does not destroy proteoglycans. He pointed out in a personal communication (2003) that EDTA is actually used to harvest cells in culture that are subsequently stained for proteoglycan, and would not be used if it had such a damaging effect.

The caller whose query led to our study of this stain provided electronic images of the SOFG stains she conducted in her laboratory. Her staining patterns were consistent with results obtained in our lab, but the color contrast was far more brilliant than ours, which I believe is due to minor differences in our respective stain protocols. She also did some digging and tracked down a message posted on the Histonet listserv that could be the genesis of all this confusion.

The message on Histonet was a reply by Gayle Callis to an inquiry regarding decalcification and poor SOFG staining. In her posting,

Callis stated, "EDTA can extract proteoglycans and this extraction may result in altered tinctoral staining." Perhaps some have interpreted those remarks to suggest that SOFG staining could not be carried out accurately on EDTA decalcified bone. It is noteworthy that the original report by Rosenberg was carried out on frozen sections of undecalcified articular cartilage.<sup>2</sup> In a recent personal communication (2003), Callis recommends the use of normal, undecalcified cartilage along with an EDTA decalcified cartilage control when cartilage studies are undertaken in order to appreciate the effects of EDTA decalcification on staining.

Tinctoral differences in SOFG staining may be the result of several factors including differences between species, between articular cartilage and growth plate cartilage, and differences in stain protocols, as well as the effects of particular fixatives and decalcifying agents. Therefore, if consistent tinctoral quality is required, it is imperative

# Say good night to overnight processing.

The new Tissue-Tek® Xpress™ Rapid Tissue Processor marks a new dawn in the practice of clinical pathology. For the first time in histology, same-day specimen diagnosis is possible.

- Continuous throughput of 120 specimens per hour delivers dramatic improvements in laboratory work flow
- Biopsy and routine specimens can be processed simultaneously, offering flexibility and eliminating batching
- Microwave technology accelerates processing and provides uniform distribution of energy for consistent high-quality results

- Novel system of four onboard reagents are packaged ready to use, and provide significant reagent volume savings
- Reagents contain no formalin or xylene, preserving DNA, RNA, and proteins in the paraffin block
- The Xpress™ processing method is compatible with molecular pathology techniques



**Tissue-Tek® Xpress™**

Rapid Tissue Processor



Sakura Finetek U.S.A., Inc. • 1750 West 214<sup>th</sup> Street  
Torrance, CA 90501 U.S.A. • Phone: (800) 725-8723

©2004 Sakura Finetek U.S.A., Inc.

[www.sakuraus.com](http://www.sakuraus.com)



SAKURA

Innovation you can trust

to use the appropriate control that will take all these factors into account.

Posting questions on Histonet is easy and often tempting for those who don't want to weed through a lot of reference material but who simply need a quick, expedient answer. However, an accurate understanding of the technical and chemical details may well be lacking in the Histonet response. This may lead us to apply specific concepts to other problems or situations in an erroneous manner. The reader has a responsibility to question and understand the concepts thoroughly in order to avoid incorrect conclusions or the dissemination of misinformation.

### Acknowledgments

I would like to acknowledge the following individuals who contributed technical information that led to the conclusions drawn in this article:

- Gayle Callis, Veterinary Molecular Biology,  
Montana State University, Bozeman, MT  
Vicki Kalscheur, University of Wisconsin  
School of Veterinary Medicine, Madison, WI  
Liu Lichu, MD, Research Associate,  
Arkansas Children's Hospital Research Institute,  
Little Rock, AR  
Martin Ronis, PhD, Professor in Pharmacology  
and Toxicology, UAMS, Associate Director,  
Arkansas Children's Nutrition Center,  
Little Rock, AR  
Ralph Sanderson, PhD, Professor of Pathology,  
Arkansas Cancer Research Center,  
University of Arkansas for Medical Sciences,  
Little Rock, AR  
Larry Suva, PhD, Director, Center for Orthopaedic  
Research, University of Arkansas for Medical  
Sciences, Little Rock, AR  
Frances L. Swain, Center for Orthopaedic Research,  
University of Arkansas for Medical Sciences,  
Little Rock, AR

The author thanks Bill Hogue, Center for Orthopaedic Research, UAMS, Little Rock, AR, for photographic and computer-related assistance.

### References

1. Kalscheur VL. Bone and cartilage changes in osteoarthritis: a proteoglycan stain. *Histologic*. 2001;34:14-15.
2. Callis G, Sterchi D. Decalcification of bone: literature review and practical study of various decalcifying agents, methods and their effects on bone histology. *J Histotech*. 1998;21:49-58.

## Immunohistochemical Staining Techniques to Demonstrate *Treponema pallidum* Spirochetes

Hazel Dalton, BA, HT,  
QIHC (ASCP)  
Lydia Shanks, HT (ASCP)  
Roxanne Walden, BS, HTL,  
QIHC (ASCP)  
University of Texas  
M. D. Anderson Medical Center  
Houston, TX  
[hdalton@mdanderson.org](mailto:hdalton@mdanderson.org)

### Abstract

Immunohistochemical (IHC) staining techniques are described that utilize a polyclonal anti-*Treponema pallidum* spirochetes antibody with colloidal gold and horseradish peroxidase detection systems to demonstrate spirochetes in formalin-fixed, paraffin-embedded tissue sections for light microscopy. The immunostaining reaction for the colloidal gold detection system is visualized with immunogold silver staining (IGSS) enhancement. The immunostaining reaction with the horseradish peroxidase detection system is visualized using DAB (3, 3'-diaminobenzidine) and AEC (3-amino-9-ethylcarbazole).

The IHC techniques used to demonstrate the organisms exhibit more specific staining than traditional silver techniques because only the organisms are being stained in the tissue, readily distinguishing them from the background. Additional work is needed to determine the usefulness of these techniques in the histopathology laboratory.

### Introduction

*Treponema pallidum* is the causative agent for syphilis. The diagnosis of syphilis in tissue samples is dependent upon the accurate demonstration of the

*T pallidum* organism. Traditionally, demonstration of these organisms in tissue sections for light microscopy is performed using silver impregnation methods such as Warthin Starry or Steiner & Steiner. These methods are sometimes very cumbersome and do not always give consistent and reproducible results. We describe immunohistochemistry (IHC) staining techniques that utilize a polyclonal anti-*Treponema pallidum* spirochetes antibody with colloidal gold and horseradish peroxidase detection systems to demonstrate spirochetes in formalin-fixed, paraffin-embedded tissue sections for light microscopy. We found that with these methods, the organisms are readily identified without the nonspecific staining that is often present when staining with traditional silver staining methods.

### Materials and Methods

Formalin-fixed, paraffin-embedded specimens that were known to contain spirochete organisms were sectioned at 4-6 microns, placed on Superfrost Plus™ slides (Erie Scientific, Portsmouth, NH), and dried at 58°-60°C. Sections were deparaffinized and hydrated to distilled water. A routine hematoxylin and eosin (H&E) stain and a modification of the traditional Steiner & Steiner silver stain were performed. Heat-induced epitope retrieval (HIER) using citrate buffer pH 6.0 in a vegetable steamer was performed on the sections stained with IHC. Sections were immunostained with rabbit anti-*Treponema pallidum* spirochetes (Biocare Medical, Walnut Creek, CA). Specifications for the antibody are detailed in Table 1. Colloidal gold detection was achieved using the Histogold Kit (Zymed Laboratories Inc., San Francisco, CA), as well as a horseradish peroxidase (HRP) conjugated universal polymer (MACH2) detection system (Biocare Medical, Walnut Creek, CA). Each was used according to the manufacturer's specifications.

Immunostaining reactions for the colloidal gold detection system were visualized using immunogold silver staining (IGSS) enhancement. Immunostaining reactions for horseradish peroxidase detection systems were visualized using aminoethylcarbazole (AEC) and/or diaminobenzidine (DAB) chromogen substrates. Specifications for detection systems and counterstains used are detailed in Table 2. The immunostains were evaluated to determine which procedure allowed for easy recognition of the organisms.

### Controls

To verify the specificity of light microscopy staining with Steiner & Steiner and immunostaining reactions, tissue sections of rat small intestine known to contain spirochete organisms (Newcomer Supply, Middleton, WI) were included in each staining run.

### Immunogold Silver Staining (IGSS) Technique to Demonstrate *Treponema pallidum* Spirochetes

Formalin-fixed, paraffin-embedded tissue sections are cut at 3-5  $\mu$ , placed on Superfrost Plus™ slides, dried at 58°-60°C, deparaffinized, and hydrated to distilled water. Use chemically cleaned glassware after step 6.

1. Perform heat-induced epitope retrieval (HIER) by placing sections into citrate buffer pH 6.0, and heating to 90°C for 45 minutes in a vegetable steamer. Allow sections to return to room temperature before continuing.
2. Rinse in several changes of distilled water and then place in phosphate buffered saline (PBS).
3. Apply normal goat serum (NGS) to suppress nonspecific background staining.

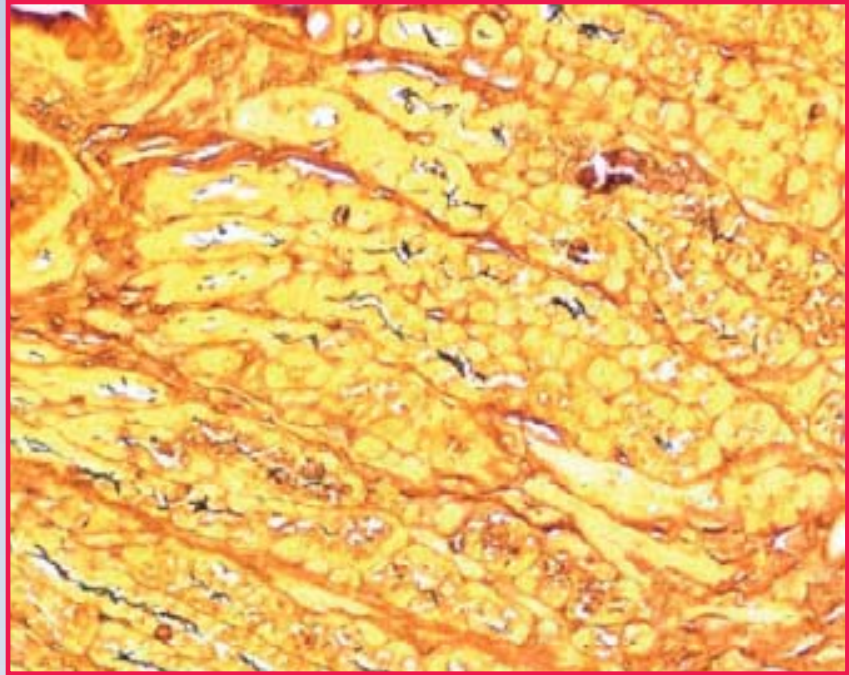


Fig. 1. Steiner & Steiner silver stain; spirochete organisms are stained black but the background is often noisy, making organism identification difficult. 400X

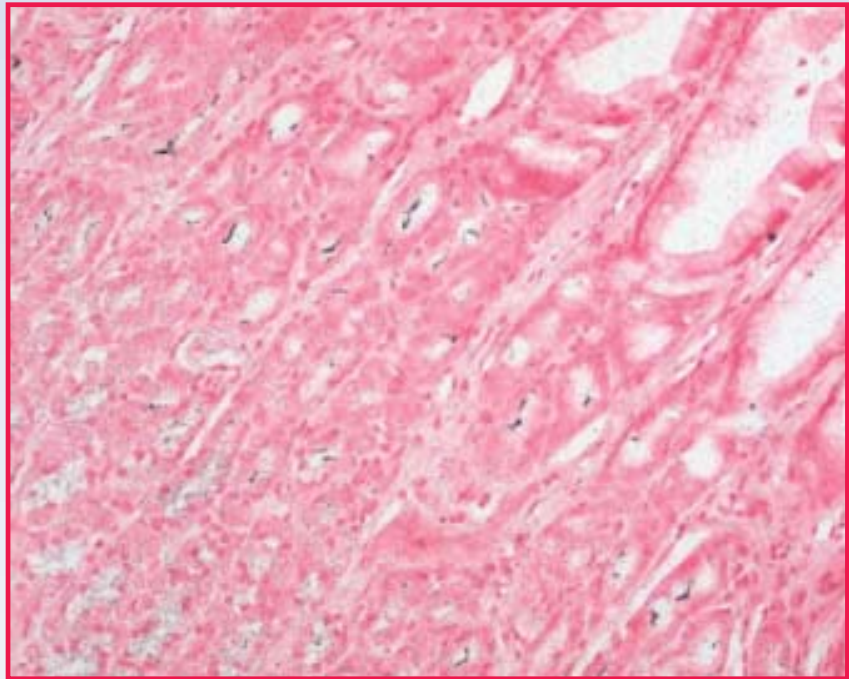


Fig. 2. Immunogold IHC stain with silver enhancement and nuclear fast red counterstain. Organisms are stained black against a pink background. 400X

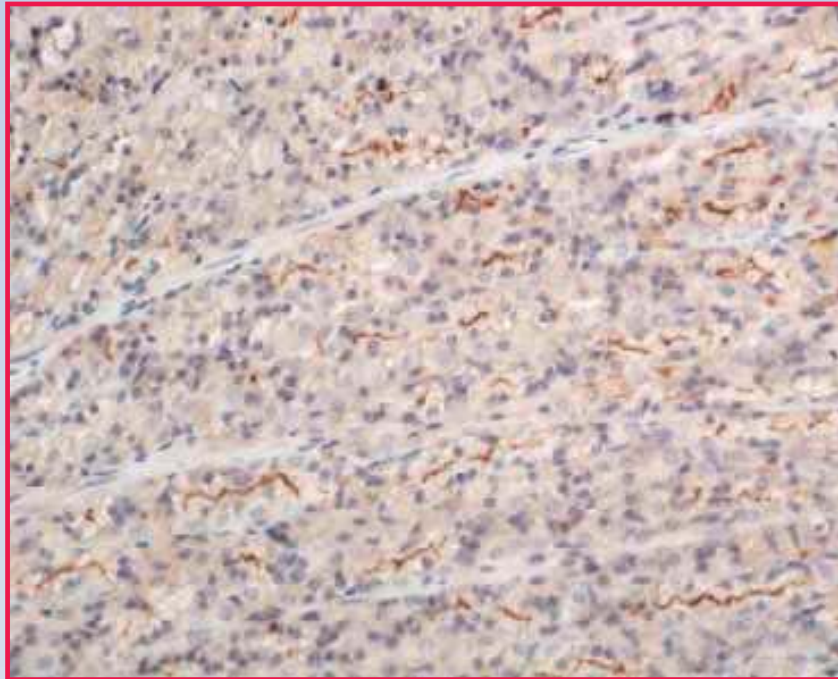


Fig. 3. IHC staining with horseradish peroxidase detection and DAB chromogen. Hematoxylin counterstain. 400X

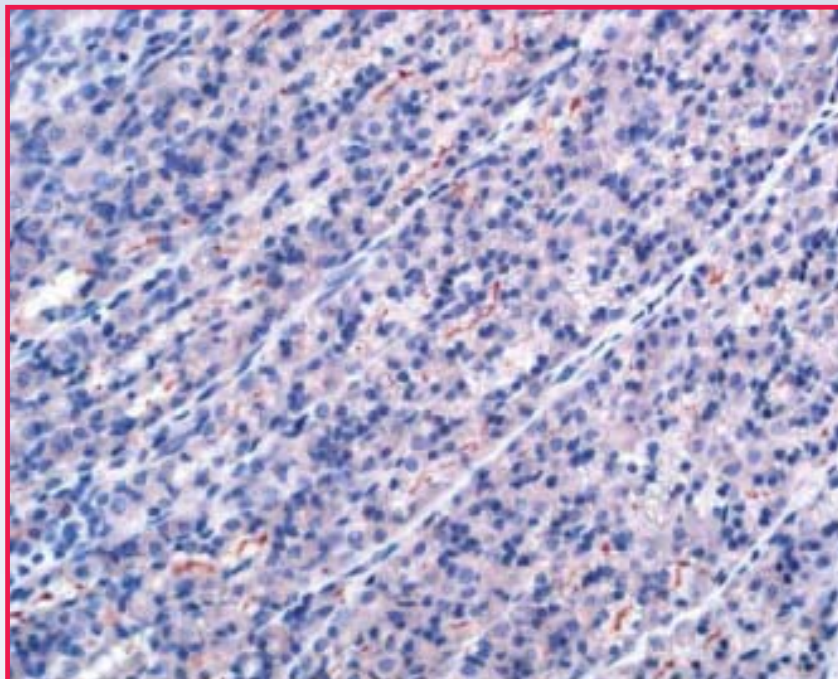


Fig. 4. IHC staining with horseradish peroxidase detection and AEC chromogen. Hematoxylin counterstain. 400X

**Incubate:** 20 minutes at room temperature

4. Remove excess NGS from around tissue sections and apply rabbit anti-*Treponema pallidum* antibody.

**Incubate:** Overnight in a refrigerator at 4°C

5. Wash sections in PBS three times.
6. Apply colloidal gold conjugated goat anti-rabbit IgG.

**Incubate:** 30 minutes at room temperature

7. Wash in PBS three times.
8. Apply silver enhancement solution according to manufacturer's instructions.

**Incubate:** 5 minutes

**NOTE:** Monitor silver development microscopically. If not dark enough, rinse slides in PBS and apply fresh silver enhancement solution for another 5 minutes.

9. Rinse well with distilled water.
10. Counterstain as desired: metanil yellow or nuclear fast red (NFR).
11. Dehydrate, clear, and mount in Permount™ (Fisher Scientific).

**Stain Results:** Spirochetes appear crisp and black against a yellow background if counterstained with metanil yellow, or against a red background if counterstained with NFR.

#### **Immunohistochemistry Technique to Demonstrate *Treponema pallidum***

Formalin-fixed, paraffin-embedded tissue sections are cut at 3-5 μ, placed on Superfrost Plus™ slides, dried at 58°-60°C, deparaffinized, and hydrated to distilled water.



**TABLE 1  
ANTIBODY SPECIFICATIONS**

Antibody	Source	Lot #	Animal	Dilution	Special Treatment
<i>Treponema pallidum</i>	Biocare	060201	Rabbit	Prediluted	HIER

**TABLE 2  
DETECTION SYSTEMS/CHROMOGEN**

Detection System	Source	Lot #	Animals	Chromogen	Counterstain
Polymer (HRP)	Biocare	031203	Universal M, R	AEC, DAB	Hematoxylin
Colloidal Gold	Zymed	20973430R	Rabbit	N/A	Metanil Yellow Nuclear Fast Red (NFR) vI, k

1. Perform heat-induced epitope retrieval (HIER) by placing sections into citrate buffer pH 6.0, and heating to 90°C for 45 minutes in a vegetable steamer. Allow sections to return to room temperature before continuing.

2. Rinse in several changes of distilled water.

3. Place sections in 3% H<sub>2</sub>O<sub>2</sub> solution for 10 min to block endogenous peroxidase. (Prepare in methanol or distilled water.)

4. Rinse in several changes of distilled or deionized H<sub>2</sub>O and then place in PBS.

5. Apply normal goat serum (NGS) to suppress nonspecific background staining.

**Incubate:** 20 minutes

6. Remove excess NGS from around sections and apply rabbit anti-*Treponema pallidum* antibody.

**Incubate:** Overnight in a refrigerator at 4°C

7. Wash sections in PBS three times.

8. Apply HRP Universal Polymer.

**Incubate:** 45 minutes

9. Wash slides in PBS three times.

10. Apply chromogen substrate: DAB or AEC.

**Incubate:** until desired color intensity

11. Wash in several changes of distilled H<sub>2</sub>O.

12. Counterstain in hematoxylin.

13. Rinse in several changes of distilled H<sub>2</sub>O; intensify nuclear staining with a bluing agent.

14. Rinse in several changes of distilled H<sub>2</sub>O. (If AEC is used, mount with aqueous mounting medium; if DAB is used, dehydrate, clear, and mount in Permount.<sup>TM</sup>)

**Stain Results:** Spirochetes using AEC chromogen stain red against a blue background. Spirochetes using DAB chromogen stain

brown-black against a blue background.

**Results**

As seen in Figs. 2, 3, and 4, IHC staining exhibits more specific staining of the organisms than the traditional silver impregnation techniques shown in Fig. 1. Only the organisms are stained in the immunostained preparations and they are readily distinguished from the background. When counterstained with metanil yellow, the sections utilizing the IGSS technique closely resemble those stained with traditional silver impregnation techniques.

**Discussion**

For this investigation, a modified Steiner & Steiner silver impregnation technique, and two IHC techniques (HRP polymer and IGSS techniques) were performed on known positive *T pallidum* controls, as well as on spirochete control slides that were purchased from Newcomer Supply. Information from the vendor indicates that their spirochete control slides are produced under carefully controlled conditions in which *T hyodysenteriae*

microorganisms purchased from American Type Culture Collection were introduced into harvested rodent organs.

Incubation time, temperature, and HIER to unmask the antigen were optimized for IHC staining. Consequently, sections underwent epitope retrieval using citrate buffer pH 6.0 and then were incubated with the primary antibody overnight at 4°C. The antibody used in the IHC techniques was a polyclonal rabbit anti-*Treponema pallidum* antibody.

The HRP polymer technique was used to localize the organisms followed by AEC and DAB chromogen substrates, before being counterstained with a modified Mayer's hematoxylin. The spirochetes stained red with the AEC substrate and brown with the DAB substrate. In tissue sections that were immunostained using the IGSS technique to localize and visualize the spirochetes, the organisms stained black against a pink-red background when using NFR as a counterstain, and against a yellow background when using metanil yellow as a counterstain.

#### Conclusion

The IHC staining techniques used in this investigation seem to be superior to traditional silver staining methods for demonstrating *T pallidum* spirochetes. The IHC techniques are reproducible and consistent, and they exhibit more specific staining than traditional silver staining techniques. Sensitivity is increased since there is excellent contrast between stained organisms and background, allowing organisms to readily stand out from the surrounding tissue. Additional work is needed in the histopathology laboratory to determine the usefulness of these techniques in the diagnosis of spirochete disease.

#### Acknowledgments

We are most appreciative for the assistance of the following students in the UTMDACC Program in Histotechnology: Patricia Amman, Gabriel Ayala, Shashi Reddy, and Olga Rodriguez.

#### References

1. Garvey W. Silver stains. *J Histotechnol.* 1996;19(3):203-209.
2. Holgate CS, Jackson P, Cowen PN, Bird CC. Immunogold-silver staining: new method of immunostaining with enhanced sensitivity. *J Histochem Cytochem.* 1983;31:938-944.
3. Lucocq JM, Roth J. Colloidal gold and colloidal silver metallic markers for light microscopic histochemistry. In: *Techniques in Immunocytochemistry.* Vol. 3. Academic Press: New York, NY; 1985:203-236.
4. Shi SR, Gu J, Kalra KL, Chen T, Cote RJ, Taylor CR. Antigen retrieval technique: a novel approach to immunohistochemistry staining on routinely processed tissue sections. *Cell Vis.* 1995;2:6-22.

## Access *HistoLogic*<sup>®</sup> Archives



Sometimes once is not enough. That's why Sakura features the *HistoLogic*<sup>®</sup> Archives on its web site at [www.sakuraus.com](http://www.sakuraus.com). Whether you want to review recent advances or decades-old innovations in histology, you can find ample material in our archives.

The *HistoLogic*<sup>®</sup> Archives enable users to access articles from past *HistoLogic*<sup>®</sup> issues dating back to 1971. Just type in a keyword in our archive search engine or look up an article by subject category. It's that simple.

The *HistoLogic*<sup>®</sup> Archives. Another resource that demonstrates Sakura dedication to histology.



# Join the Revolution.

Welcome to the latest Tissue-Tek®  
innovations in clinical pathology. Evolving  
histology  
into a new dimension  
of total automation,  
streamlined productivity,  
and enhanced workflow.

Specimen preparation is now possible  
in just 2 hours for same-day results.

See the revolution for yourself  
at NSH, Booth #601.



 **Tissue-Tek® Xpress™**  
Rapid Tissue Processor



 **Tissue-Tek® AutoTEC™**  
Automated Embedding System

Visit our web site at [www.sakuraus.com](http://www.sakuraus.com)

©2004 Sakura Finetek U.S.A., Inc.



**SAKURA**

Innovation you can trust

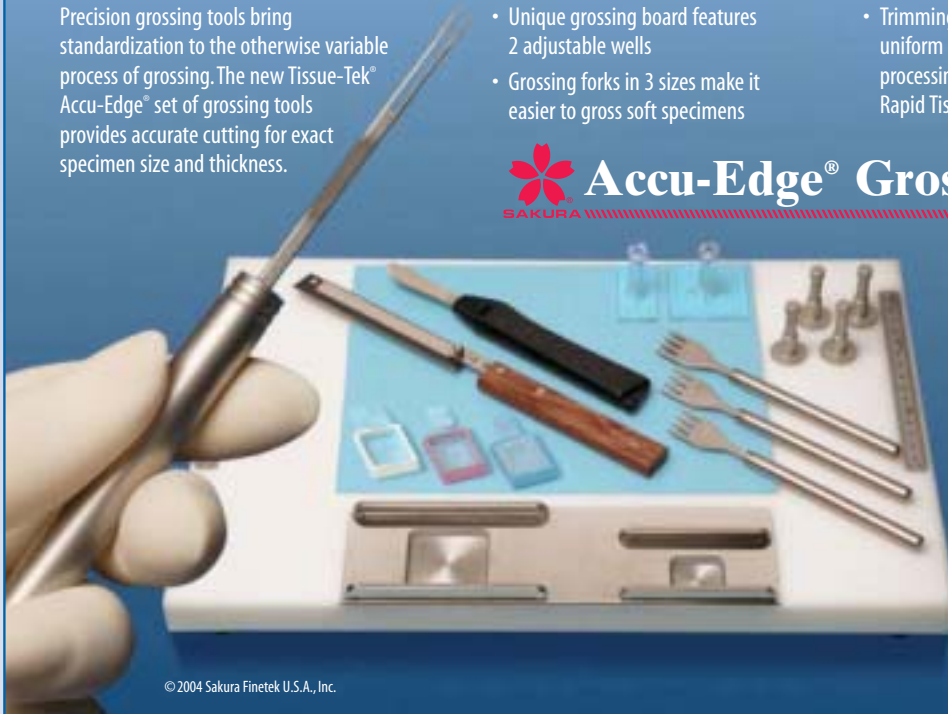# The foundation of specimen standardization

Precision grossing tools bring standardization to the otherwise variable process of grossing. The new Tissue-Tek® Accu-Edge® set of grossing tools provides accurate cutting for exact specimen size and thickness.

- Unique grossing board features 2 adjustable wells
- Grossing forks in 3 sizes make it easier to gross soft specimens

- Trimming and scalpel blades deliver uniform results for consistent tissue processing with the Tissue-Tek® Xpress™ Rapid Tissue Processor

## Accu-Edge® Grossing Tools



Visit our web site at [www.sakuraus.com](http://www.sakuraus.com)



Innovation  
you can trust

Sakura Finetek U.S.A., Inc.  
1750 West 214th Street  
Torrance, CA 90501 U.S.A.  
Phone: (800) 725-8723

© 2004 Sakura Finetek U.S.A., Inc.

To receive your own copy of **HistoLogic**® or to have someone added to the mailing list, submit home address to: Sakura Finetek U.S.A., Inc., 1750 West 214th Street, Torrance, CA 90501.

The editor wishes to solicit information, questions, and articles relating to histotechnology. Submit these to: Vinnie Della Speranza, **HistoLogic**® Editor, 165 Ashley Avenue, Suite 309, Charleston, SC 29425. Articles, photographs, etc., will not be returned unless requested in writing when they are submitted.



Sakura Finetek U.S.A., Inc.  
1750 West 214th Street  
Torrance, CA 90501

PRESORTED  
STANDARD  
U.S. POSTAGE  
**PAID**  
CAROL STREAM, IL  
PERMIT #1

**HISTOLOGIC**®  
Technical Bulletin for Histotechnology